

ANDROGRAPHIS PANICULATA EXTRACT PROTECT AGAINST ISOPROTERENOL-INDUCED MYOCARDIAL INJURY BY MITIGATING CARDIAC DYSFUNCTION AND OXIDATIVE INJURY IN RATS

SHREESH OJHA¹*, SAURABH BHARTI¹, MAHAVEER GOLECHHA¹, ASHOK K. SHARMA¹, NEHA RANI¹, SANTOSH KUMARI² and DHARAMVIR SINGH ARYA^{1*}

¹Department of Pharmacology, All India Institute of Medical Sciences, New Delhi-110029, India

²Division of Plant Physiology, Indian Agricultural Research Institute, New Delhi-110012, India

Abstract: Present study evaluated the cardioprotective effect of *Andrographis paniculata* (100, 200 or 400 mg/kg) against isoproterenol (85 mg/kg, b.w.)-induced cardiotoxicity referred as myocardial infarction in rats. Isoproterenol significantly ($p < 0.05$) decreased mean arterial pressure, heart rate, contractility and relaxation and increased left ventricular end diastolic pressure. Isoproterenol also significantly ($p < 0.05$) decreased antioxidants, superoxide dismutase, catalase, glutathione peroxidase, glutathione and increased leakage of cardiac injury markers; creatine phosphokinase-MB isoenzyme, lactate dehydrogenase concomitant to increased lipid peroxidation and histopathological perturbations. However, pretreatment with *A. paniculata* favorably restored hemodynamic parameters and left ventricular function and significantly ($p < 0.05$) prevented the depletion of endogenous antioxidants and myocyte marker enzymes as well as inhibited lipid peroxidation. Significant ($p < 0.05$) reversal of almost all the hemodynamic, biochemical and histopathological parameters by *A. paniculata* pretreatment in isoproterenol-induced cardiotoxicity depicted the cardioprotective effect of *A. paniculata*. Results showed that *A. paniculata* protected heart against cardiotoxic effects of isoproterenol by boosting endogenous antioxidant network, restoring ventricular function and maintaining structural integrity of heart.

Keywords: *Andrographis paniculata*, cardiotoxicity, isoproterenol, myocardial necrosis, infarction

Cardiac toxicity is an unintended and undesirable consequence of exposure to the drugs, including medications used for the treatment of cancer, AIDS, asthma, diabetes, inflammation and psychoses (1). Preclinical safety assessment in animals has demonstrated high predictability of cardiotoxicity in humans, with up to 80% concordance between preclinical and clinical studies (2, 3). Preclinical assessment of drugs useful in cardiotoxicity often involves the use of isoproterenol, a potent synthetic catecholamine and a powerful nonselective β -agonist. Isoproterenol is used to induce infarct-like lesions in heart of animals through an exaggerated effect (4). The appearance of myocardial lesions after isoproterenol administration provides an indisputable evidence of cardiac injury and is routinely utilized for drug screening for cardioprotection (5). Isoproterenol-induced cardiotoxicity, often referred as myocardial necrosis, morphologically resembles the coagulative myocytolysis or myofibrillar degeneration, which is one of the signs of acute myocar-

dial infarction (AMI) in humans. Some of the mechanisms, proposed to explain isoproterenol-induced damage to cardiomyocytes, includes hypoxia due to myocardial hyperactivity and coronary hypotension, Ca^{2+} overload, depletion of energy reserves and excessive production of free radicals resulting from oxidative metabolism of catecholamines (7–9). In pharmacological studies, it is a well authenticated *in vivo* animal model for the screening of cardioprotective agents and the mechanistic insight (6–9).

At present, natural products and medicinal herbs are acquiring much attention as potential source of antioxidants as they serve as excellent candidates against reactive oxygen species (ROS)-induced pathologies. Several medicinal herbs, or herb based drugs have been shown to delay the progression of ischemic injury and protect from risk factors of cardiovascular diseases, as these agents render resistance to the heart against ischemic injury and prevent from the deleterious consequences of oxidative stress on heart function (10–12). Among

* Corresponding author: e-mail: dsarya16@hotmail.com; phone: +911126594266; fax: 911126584121

the several popular medicinal herbs, *Andrographis paniculata* Nees (family: Acanthaceae) popularly known as 'Kalmegh' is used as a folklore cardiovascular remedy in India, China, and other Southeast Asian countries (13). It is a common ingredient of herbal formulations indicated for the cardiovascular diseases and known to improve immunity, therefore referred as 'Indian Echinacea' being similar to a popular western immunostimulatory herb, Echinacea. The pharmacological potential of *A. paniculata* such as anti-inflammatory (14), immunostimulatory (14), hepatoprotective (15), antihyperglycemic (16), and cardiovascular activities (13, 17) has been demonstrated. Despite numerous studies, the exact mechanism underlying its therapeutic effects still lacks substantial data. In particular, no study has yet addressed its effect on cardiac function and mechanism in myocardial ischemic injury. The aim of the present study was to evaluate the cardioprotective potential of *A. paniculata* in experimental model of myocardial ischemic injury. In the present study, isoproterenol was used to produce myocardial necrosis in experimental rats and *A. paniculata* was administered before and during the onset of ischemic injury. To assess the deleterious effects of oxidative injury, various hemodynamic and ventricular functional parameters were recorded. To delineate the mechanism of protection, effect of *A. paniculata* on endogenous antioxidant system, lipid peroxidation and markers of myocardial injury were studied in heart homogenate. Further, the protective activities of *A. paniculata* on heart were supported by histopathological studies.

EXPERIMENTAL

Plant extract and chemicals

The hydroalcoholic lyophilized extract of *A. paniculata* was procured from Sanat Products Ltd., New Delhi, India. The standardized extract contained 10% w/w total andrographolides. All the chemicals used in the present study were of analytical grade and obtained from the following scientific companies: Sigma (St. Louis, MO, USA), Merck (Mumbai, India), Ranbaxy (New Delhi, India), Sisco (Mumbai, India) and Qualigens (Mumbai, India). Isoproterenol hemisulfate was obtained from Sigma Chemicals Co. (St. Louis, MO, USA).

Experimental animals

The study protocol was reviewed and approved by the Institutional Animal Ethics Committee of All India Institute of Medical Sciences, New Delhi and conducted in accordance to Indian National Science

Academy Guidelines for the Use and Care of Experimental Animals. Male albino Wistar rats of 10–12 week old, weighing 150–200 g were obtained from the Central Animals House facility of All India Institute of Medical Sciences, New Delhi, India. The animals were kept in polypropylene cages, each cage containing a maximum of four animals. The animals were housed under standard laboratory conditions ($25 \pm 5^\circ\text{C}$, relative humidity $60 \pm 10\%$, 14 h dark/10 h light photoperiod) in departmental animal house. Animals were fed commercial pellet diet and tap water *ad libitum*.

Induction of experimental myocardial injury

Isoproterenol hemisulfate (20%) was dissolved in normal saline under sterile condition and used within 10 min of preparation. Isoproterenol (85 mg/kg) was administered subcutaneously (*s.c.*) for two consecutive days at an interval of 24 h to induce myocardial injury (12).

Experimental design

Animals of group I, designated as vehicle control group, were orally administered normal saline once daily for 31 days; and on day 29 and 30, 0.3 mL of normal saline was injected subcutaneously at an interval of 24 h. Animals of group II, designated as isoproterenol control group, were orally administered 0.9% of normal saline once daily for 31 days; and on days 29 and 30, isoproterenol (85 mg/kg) was injected subcutaneously at an interval of 24 h. Animals of group III, IV and V were designated as *A. paniculata* treatment group and were administered *A. paniculata* 100, 200 or 400 mg/kg orally for 31 days. On days 29 and 30, the rats of *A. paniculata* treated groups were further administered subcutaneous injections of isoproterenol (85 mg/kg) at an interval of 24 h.

Assessment of hemodynamic and left ventricular dynamics

On day 31, animals of all experimental groups were anesthetized intraperitoneally with pentobarbital sodium (60 mg/kg) and atropine (0.4 mg/kg) was co-administered to maintain heart rate especially during surgery and to reduce tracheobronchial secretions. The neck was opened to perform tracheostomy and ventilated with room air from a positive pressure ventilator (Inco, Ambala, India) using compressed air at a rate of 90-strokes/min and a tidal volume of 10 mL/kg. Ventilator setting and oxygen were adjusted as needed to maintain the arterial blood gas parameters within the physiological range. Left jugular vein was cannulated with poly-

ethylene tube for continuous infusion of saline solution (0.9%) and right carotid artery was cannulated with a heparinized saline filled cannula. The cannula was connected with Cardiosys CO-101

(Experimentria, Hungary) using a pressure transducer and the signals were amplified by means of an amplifier for measurement of mean arterial pressure (MAP) and heart rate (HR). Left thoracotomy was

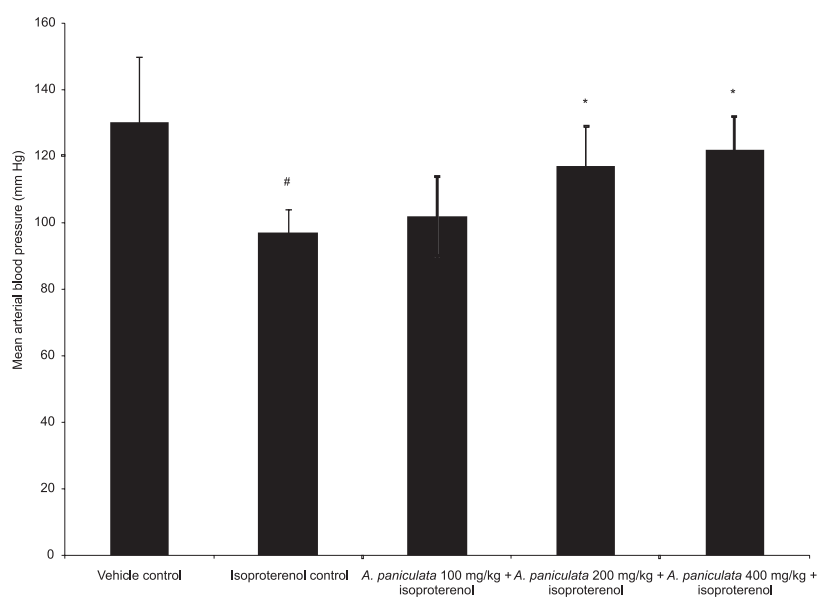


Figure 1. Effect of *A. paniculata* pretreatment on mean arterial pressure. Values are the mean \pm SD of 6 rats in each group. * $p < 0.05$, when compared to vehicle control; # $p < 0.05$, when compared to isoproterenol control

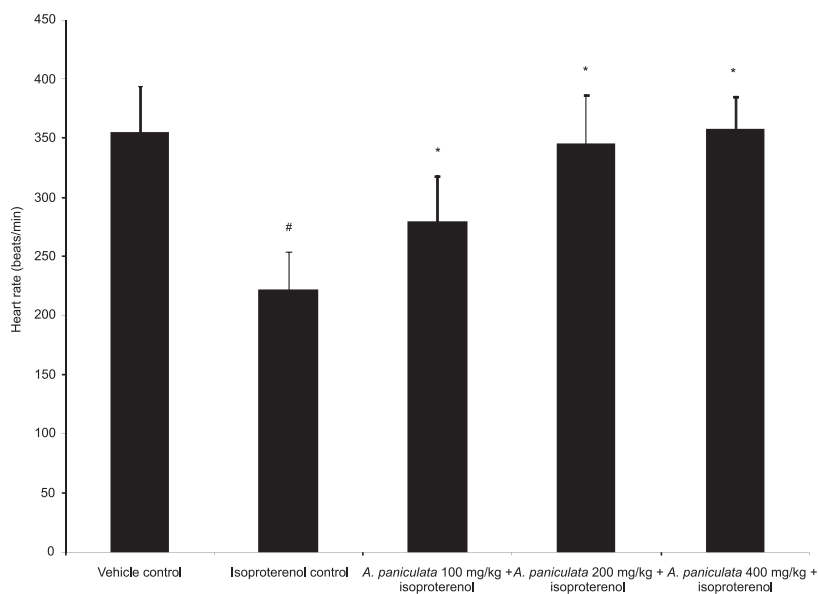


Figure 2. Effect of *A. paniculata* pretreatment on the heart rate. Values are the mean \pm SD of 6 rats in each group. * $p < 0.05$, when compared to vehicle control; # $p < 0.05$, when compared to isoproterenol control

performed at the fourth-fifth intercostal space on left side and heart was exposed. After incising pericardium, heart was exteriorized by gentle pressure on ribs. A sterile metal cannula (1.5 mm bore) was introduced into cavity of left ventricle from posterior apical region of heart for measuring left ventricular dynamics such as left ventricular peak positive pressure development; (+)LVdP/dt, represent contractility, left ventricular negative pressure development; (-)LVdP/dt, represent relaxation, and left ventricular end diastolic pressure (LVEDP), a surrogate marker of preload. The cannula was connected to a pressure transducer (Gould Statham P23ID, USA) through a pressure-recording catheter on Polygraph (Grass 7D, USA). After the stabilization time of 10 min, tracings were recorded on polygraph paper following baseline measurements at different standardized sensitivity and speed. Thoracic cavity was covered with saline soaked gauze after surgery to prevent heart from drying.

Biochemical analysis of heart

After recording cardiac function, rats were euthanized and heart was excised and a 10% homogenate was prepared in phosphate buffer (50 mM, pH 7.4). An aliquot of 0.5 mL heart homogenate was used for assay of reduced glutathione (GSH) and malonaldehyde (MDA), a stable product of lipid peroxidation following methods described by Moron et al. (18) and Ohkawa et al. (19). Rest of the homogenate was centrifuged at $4930 \times g$ for 15 min and the supernatant was used for estimation of antioxidant enzymes: superoxide dismutase (SOD) (20), catalase (CAT) (21) and glutathione peroxidase (GPx) (22). One unit of SOD was defined as the amount of enzyme required to produce 50% inhibition of epinephrine auto-oxidation (20). One unit of CAT activity represents one micromole of H_2O_2 decomposed per min at $25^\circ C$ (21). One unit of GPx enzyme activity was defined

as one nanomole of NADPH utilized per min at $37^\circ C$ (22). The myocyte injury markers; creatine phosphokinase-MB (CK-MB) isoenzyme and lactate dehydrogenase (LDH) were also estimated in the hearts. CK-MB isoenzyme was estimated spectrophotometrically using a kit from Spin react, Spain. LDH activity in heart was measured by the method of Cabaud and Wroblewski (23). Protein content in heart was estimated by the method of Lowry et al. (24).

Statistical analysis

Descriptive statistics such as the mean and standard deviation were calculated for each variable in the experimental groups. Data were compared using one-way ANOVA following *post hoc* analysis, Bonferroni multiple comparison test and the differences were considered significant at $p < 0.05$.

RESULTS

Effect on arterial pressure and heart rate

Isoproterenol produced a significant ($p < 0.05$) decline of MAP in comparison to vehicle treated group (Fig. 1). However, *A. paniculata* at all doses except 100 mg/kg produced a significant ($p < 0.05$) restoration of MAP in comparison to isoproterenol control group (Fig. 1). Isoproterenol has also significantly ($p < 0.05$) decreased heart rate when compared to the vehicle treated group (Fig. 2). *A. paniculata* pretreatment at all doses (100, 200 and 400 mg/kg) significantly ($p < 0.05$) prevented decline in heart rate (Fig. 2).

Effect on left ventricle function

A significant ($p < 0.05$) reduction in left ventricular peak positive and negative [(+)dP/dt and (-)dP/dt] pressure was observed in the isoproterenol control group as compared to vehicle treated group (Table 1). Pretreatment with *A. paniculata* (100 and

Table 1. Effect of *A. paniculata* pretreatment on left ventricular dynamics.

Treatment groups	+LVdP/dt (mmHg/s)	-LVdP/dt (mmHg/s)	LVEDP (mmHg)
Vehicle control	3554.52 ± 113.33	3192.25 ± 165.50	4.85 ± 0.55
Isoproterenol control	2835.45 ± 115.0*	2515.55 ± 145.40*	8.60 ± 1.36*
<i>A. paniculata</i> 100 mg/kg + isoproterenol	2920.50 ± 107.85	2585.45 ± 132.00	6.90 ± 0.84*
<i>A. paniculata</i> 200 mg/kg + isoproterenol	3216.66 ± 112.20*	2905.45 ± 136.25*	6.26 ± 0.95*
<i>A. paniculata</i> 400 mg/kg + isoproterenol	3305.42 ± 132.46*	2975.60 ± 141.65*	5.65 ± 1.27*

Values are the mean ± SD of 6 rats in each group. * $p < 0.05$, when compared to vehicle control; # $p < 0.05$, when compared to isoproterenol control.

200 mg/kg) significantly ($p < 0.05$) prevented decline in (+)LVdP/dt and (-)LVdP/dt as compared to isoproterenol control group (Table 1). However, *A. paniculata* 100 mg/kg failed to improve the

(+)LVdP/dt and (-)LVdP/dt (Table 1). In isoproterenol control group, a significant ($p < 0.05$) increase in LVEDP was observed as compared to vehicle treated group (Table 1). *A. paniculata* pre-

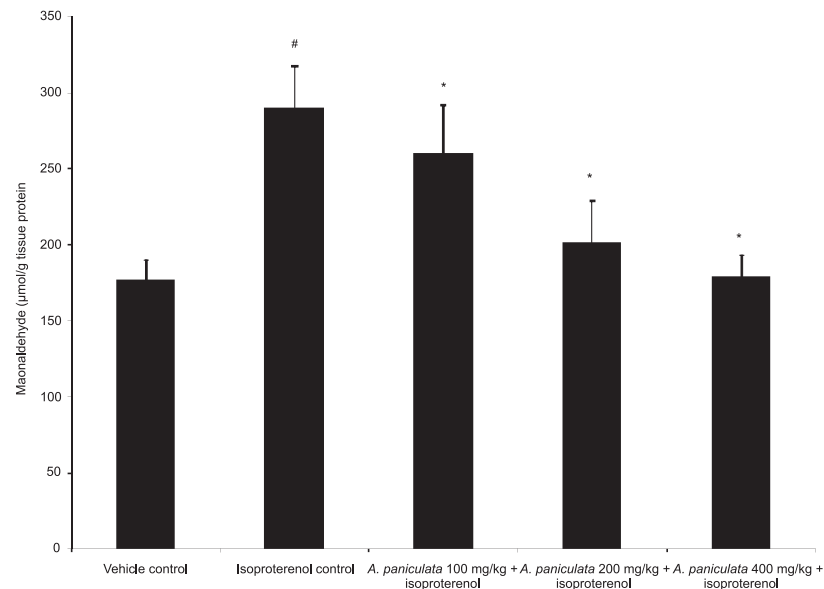


Figure 3. Effect of *A. paniculata* pretreatment on lipid peroxidation product (MDA). Values are the mean \pm SD of 6 rats in each group. * $p < 0.05$, when compared to vehicle control; # $p < 0.05$, when compared to isoproterenol control

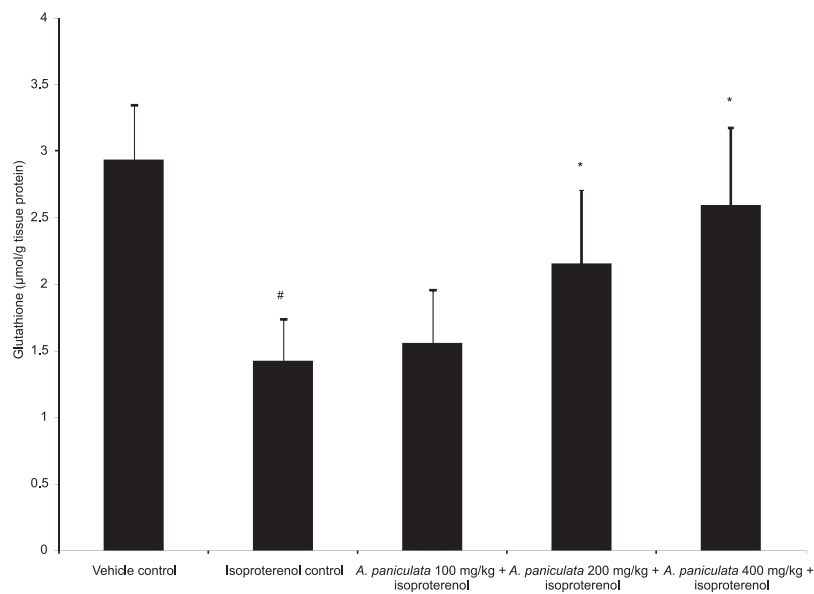


Figure 4. Effect of *A. paniculata* pretreatment on glutathione (GSH) content. Values are the mean \pm SD of 6 rats in each group. * $p < 0.05$, when compared to vehicle control; # $p < 0.05$, when compared to isoproterenol control

Table 2. Effect of *A. paniculata* pretreatment on myocyte injury marker enzymes.

Treatment groups	CK-MB (IU/mg protein)	LDH (IU/mg protein)
Vehicle control	172.40 ± 24.63	228.40 ± 27.32
Isoproterenol control	62.58 ± 25.77*	96.54 ± 21.45*
<i>A. paniculata</i> 100 mg/kg + isoproterenol	99.44 ± 23.65 [#]	170.62 ± 31.44 [#]
<i>A. paniculata</i> 200 mg/kg + isoproterenol	148.76 ± 27.80 [#]	178.20 ± 28.55 [#]
<i>A. paniculata</i> 400 mg/kg + isoproterenol	166.50 ± 32.26 [#]	206.46 ± 23.27 [#]

Values are the mean ± SD of 6 rats in each group. * p < 0.05, when compared to vehicle control; [#] p < 0.05, when compared to isoproterenol control.

Table 3. Effect of *A. paniculata* pretreatment on activities of myocardial antioxidant enzymes.

Treatment groups	SOD (u/mg protein)	CAT (u/mg protein)	GPx (u/mg protein)
Vehicle control	7.94 ± 2.90	21.90 ± 3.12	0.98 ± 0.23
Isoproterenol control	3.48 ± 1.36*	11.78 ± 2.20*	0.31 ± 0.14*
<i>A. paniculata</i> 100 mg/kg + isoproterenol	6.31 ± 2.02 [#]	12.15 ± 2.85	0.34 ± 0.19
<i>A. paniculata</i> 200 mg/kg + isoproterenol	6.98 ± 2.12 [#]	20.84 ± 8.62 [#]	0.62 ± 0.25 [#]
<i>A. paniculata</i> 400 mg/kg + isoproterenol	7.53 ± 1.88 [#]	24.75 ± 5.90 [#]	0.75 ± 0.30 [#]

Values are the mean ± SD of 6 rats in each group. * p < 0.05, when compared to vehicle control; [#] p < 0.05, when compared to isoproterenol control.

Table 4. Histopathological changes in myocardium of different experimental groups.

Treatment groups	Myonecrosis	Inflammation	Edema
Vehicle control	–	–	–
Isoproterenol control	++++	+++	+++
<i>A. paniculata</i> 100 mg/kg + isoproterenol	+	++	+
<i>A. paniculata</i> 200 mg/kg + isoproterenol	+	–	+
<i>A. paniculata</i> 400 mg/kg + isoproterenol	–	–	–

(–) nil, (+) mild, (++) moderate, (+++) severe.

treatment at all doses (100, 200 and 400 mg/kg) has produced a significant (p < 0.05) reduction of LVEDP as compared to isoproterenol control group (Table 1).

Effect on lipid peroxidation and reduced glutathione in heart

Isoproterenol administration produced a significant (p < 0.05) increase in lipid peroxidation characterized by raised formation of lipid peroxidation product, MDA in heart as compared to vehicle treated group (Fig. 3). *A. paniculata* pretreatment at all doses (100, 200 and 400 mg/kg) significantly (p < 0.05) decreased myocardial MDA level as compared to isoproterenol control group (Fig. 3). Concomitant

to increased lipid peroxidation, a significant (p < 0.05) decrease in GSH content was observed in the isoproterenol control group as compared to vehicle treated group (Fig. 4). However, *A. paniculata* at all doses except 100 mg/kg prevented the depletion of GSH content from heart (Fig. 4).

Effect on myocyte specific enzymes, CK-MB and LDH in heart

Isoproterenol-induced myocardial necrosis produced a significant (p < 0.05) decrease in CK-MB and LDH in hearts as compared to vehicle treated rats (Table 2). A significant (p < 0.05) increase in CK-MB and LDH activity in heart was observed with all doses (100, 200 and 400 mg/kg) of *A. pan-*

iculata pretreatment compared to isoproterenol control group (Table 2).

Effect on antioxidant enzymes in heart

A significant ($p < 0.05$) decrease in the activities of antioxidant enzymes, SOD, CAT and GPx was observed in isoproterenol control rats compared to vehicle treated rats (Table 3). Pretreatment with *A. paniculata* at all doses (100, 200 and 400 mg/kg) significantly ($p < 0.05$) prevented the decrease of SOD, CAT and GPx in heart compared to isoproterenol control. However, *A. paniculata* 100 mg/kg

failed to significantly restore CAT and GPx activity (Table 3).

Effect on histopathology of the heart

The histopathological changes were graded and are summarized in Table 4. Histopathological examination of the myocardium of vehicle control animals showed clear integrity of myocardial cell membrane (Fig. 5A). The endocardium and pericardium appeared within the normal limits and did not show inflammatory cell infiltration, edema or inflammation. However, the heart tissues of isopro-

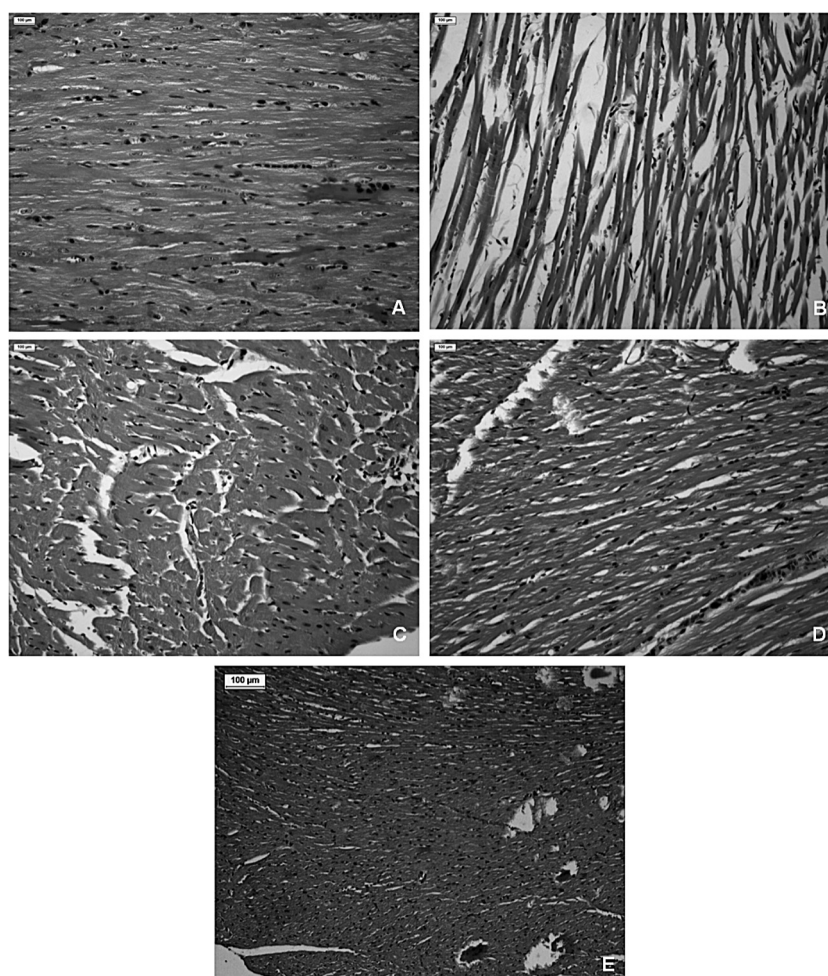


Figure 5. Light micrograph of rat's myocardium of (A) vehicle control group showing normal architecture of myocardium (H&E, 100×). (B) Isoproterenol control group showing confluent focal necrosis of myofibrils, edema, phagocytosis and fibroblastic proliferation with infiltration of inflammatory cells and extravasations of red blood cells (H&E, 100×). (C) *A. paniculata* 100 mg/kg + isoproterenol showing slightly myocardial necrosis, vacuoles, edema with inflammatory cells (H&E, 100×). (D) *A. paniculata* 200 mg/kg + isoproterenol showing predominantly normal myocardium with reduced myocardial necrosis and edema (H&E, 100×). (E) *A. paniculata* 400 mg/kg + isoproterenol showing near normal myocardial architecture with lessened necrosis and edema (H&E, 100×)

terenol-treated rats showed widespread myocardial disorganization and subendocardial necrosis along with infiltration of lymphocytes and macrophages (Fig. 5B) as compared to the vehicle control. Pretreatment with *A. paniculata* (100, 200 and 400 mg/kg, respectively) have reduced the degree of necrosis, edema along with reduced infiltration of inflammatory cells (Fig. 5C, 5D and 5E). Reduction in severity of myocardial injury by *A. paniculata*, as observed in histological examination, demonstrated the myocardial salvage against necrotic lesions caused by isoproterenol.

DISCUSSION AND CONCLUSION

Present study demonstrates the cardioprotective effect of *A. paniculata* in isoproterenol-induced cardiotoxicity as evidenced by improved antioxidant defense system, attenuation of hemodynamic impairment and left ventricular dysfunction, as well as inhibition of lipid peroxidation and prevention of leakage of myocytes injury marker enzymes from heart.

Isoproterenol is a widely used chemical in toxicological studies to induce cardiac muscle injury, through an exaggerated pharmacological effect (6–8). The administration of the two subcutaneous injections of sub therapeutic doses of isoproterenol is a well established animal model of acute myocardial infarction (6). AMI is a clinical syndrome arising from sudden and persistent curtailment of myocardial blood supply, which results in the necrosis of the myocardium (25). It is usually followed by morphological, structural, biochemical and functional changes including lipid peroxidation and hyperlipidemia (6–8). It has also been shown that impaired contractile and hemodynamic function, which leads to heart failure subsequent to isoproterenol-induced free radicals, generated oxidative stress.

In the present study, isoproterenol-induced myocardial injury has been shown to produce a significant cardiac dysfunction in consonance to previous studies as evidenced by decreased MAP and HR after isoproterenol administration (6, 12). Isoproterenol also produced significant ventricular dysfunction as reflected by increased LVEDP (a surrogate marker of preload) and decreased (+)LVdP/dt and (–)LVdP/dt represent contractility and relaxation state of heart. *A. paniculata* pretreatment significantly prevented the decrease in MAP and HR (determinants of myocardial oxygen demand), thereby decreased workload and facilitated the heart to maintain myocardial oxygen balance in ischemic tissues.

Restoration of altered MAP and HR also increased blood flow through the subendocardial region, which bears the maximal burnt of ischemic insult in isoproterenol-induced myocardial infarction. By reducing preload and favorably altering inotropic [(+)LVdP/dt] and lusitropic [(–)LVdP/dt] functions of the left ventricle, *A. paniculata* pretreatment might have improved the perfusion to subendocardium. These beneficial effects were translated into functional recovery of the heart under ischemic conditions. In the present study, andrographolide content of *A. paniculata* extract is believed to be responsible for the recovery of the hemodynamic and ventricular functions in isoproterenol-induced myocardial infarction in consonance to the previous study, wherein andrographolide has been shown to inhibit Ca^{2+} entry and favorably alter blood pressure in hypertensive rats (17).

In addition, to producing hemodynamic impairment and cardiac dysfunction, isoproterenol has been shown to induce myocardial stress by the generation of free radicals and depletion of endogenous antioxidant network in heart (4–8, 26). Free radicals have been shown to initiate lipid peroxidation result into the alteration of membrane integrity, fluidity and permeability (27). Isoproterenol significantly increased MDA level with concomitant reduction of myocardial CK-MB and LDH enzyme activity. Elevated MDA level reflects an increase in membrane permeability, which could be responsible for leakage of myocardial enzymes (CK-MB and LDH) from cardiomyocytes. CK-MB and LDH, localized in myocytes, are released during isoproterenol-induced irreversible myocardial injury and are considered as characteristic of cardiac muscle injury (28). The reduction in the leakage of CK-MB and LDH enzymes from heart as evidenced by increased levels of CK-MB and LDH in heart tissue, is suggestive of the cardioprotective effect of *A. paniculata* pretreatment.

Besides MDA, a significant decrease in myocardial GSH and endogenous antioxidant enzymes (SOD, CAT and GP_x) in the present study further confirmed the occurrence of oxidative stress. Due to disruption of endogenous antioxidant network, as observed in present study, myocardium may be more susceptible to free radicals induced ischemic injury and subsequent cascade of inflammation and injury. *A. paniculata* pretreatment significantly increased the activities of antioxidant enzymes, SOD, CAT and GP_x and prevented depletion of GSH. The observation that *A. paniculata* pretreatment prevented lipid peroxidation and improved oxidant-antioxidant balance concurs with previous

study showing its antioxidant mediated salutary effect in hypoxia and reperfusion injury (13, 29–31).

The histopathological findings of the isoproterenol-induced myocardium showed myonecrosis, edema along with infiltration of inflammatory cells and separation of cardiac muscle fibers. The neutrophils characteristically invade the myocardial tissue during ischemia and are believed to be the major source of free radicals. However, *A. paniculata* pretreatment (100, 200 and 400 mg/kg, respectively) showed reduced necrosis with mild edema and reduced inflammatory cells infiltration. The reduced inflammatory cell infiltration and almost normal appearance of cardiac muscle fiber architecture along with reduced leakage of myocyte enzymes, which depict the integrity of the myocardial cell membrane, have further confirmed the cardioprotective effect of *A. paniculata*. The active principle andrographolides and crude extract have been reported to exhibit antioxidant, antiplatelet and free radical scavenger activity therefore exerted pronounced cytoprotective effect in diseased conditions (32–35). Andrographolides have been shown to scavenge free radicals by donating the allylic hydrogen of the unsaturated lactone ring and proceeded by hydrogen abstraction from its carbon constituent (36). The distinct improvement in antioxidant status, inhibition of lipid peroxidation, also indicates the distinct antioxidant activity of *A. paniculata* in heart and provides a mechanistic approach of its use as a phytotherapeutic agent or as an adjunct with conventional agents in myocardial infarction, which is believed to be a consequence of oxidative stress and a common manifestation of cardiovascular diseases.

The present study findings demonstrate therapeutic benefits of *A. paniculata* in an integrated approach as evidenced by restoration of hemodynamic and contractile function, improvement in endogenous antioxidant defense and inhibition of lipid peroxidation. The study also has revealed that whole herb extract is an effective modality that could alleviate symptoms and might be used for prophylaxis and treatment of ischemic heart disease. The effectiveness of whole herb for cardiovascular disease is believed to be mediated by its complex composition and interactions, which can target many signal transduction and metabolic pathways and consequently, reduce cardiovascular symptoms.

Acknowledgement

The authors wish to thank to Mr. B.M. Sharma, Department of Pharmacology, All India Institute of

Medical Sciences, New Delhi for his technical assistance.

REFERENCES

- O'Brien P.J., Smith D.E.C., Knechtel T.J., Marchak M.A., Pruiimboom-Brees I., Brees D.J. et al.: *Lab. Anim.* 40, 153 (2006).
- Olson R.D., Li X., Palade P., Shadle S.E., Mushlin P.S., Gambliel H.A. et al.: *Toxicol. Appl. Pharmacol.* 169, 168 (2000).
- Gwathmey J.K., Tsaïoun K., Hajjar R.J.: *Expert Opin. Drug Metab. Toxicol.* 5, 647 (2009).
- Zhang J., Knapton A., Lipschultz S.E., Weaver J.L., Herman E.H.: *Toxicol. Pathol.* 36, 277 (2008).
- Engle S.K., Jordan W.H., Pritt M.L., Chiang A.Y., Davis M.A., Zimmermann J.L. et al.: *Toxicol. Pathol.* 37, 617 (2009).
- Goyal S.N., Arora S., Sharma A.K., Joshi S., Ray R., Bhatia J. et al.: *Phytomedicine* 17, 227 (2010).
- Todd G.L., Baroldi G., Pieper G.M., Clayton F.C., Eliot R.S.: *J. Mol. Cell. Cardiol.* 17, 317 (1985).
- Dhalla K.S., Rupp H., Beamish R.E., Dhalla N.S.: *Cardiovas. Drugs Ther.* 10 Suppl. 1, 231 (1996).
- Grimm D., Elsner D., Schunkert H., Pfeifer M., Griese D., Bruckschlegel G. et al.: *Cardiovas. Res.* 37, 91 (1998).
- Visioli F., Borsani L., Claudio G.: *Cardiovas. Res.* 47, 419 (2000).
- Shukla S.K., Gupta S., Ojha S.K., Sharma S.B.: *Nat. Prod. Res.* 24, 873 (2010).
- Nandave M., Ojha S.K., Joshi S., Kumari S., Arya D.S.: *J. Med. Food* 12, 47 (2009).
- Zhang C.Y., Tan B.K.: *J. Ethnopharmacol.* 56, 97 (1997).
- Sheeja K., Kuttan G.: *Immunopharmacol. Immunotoxicol.* 29, 81 (2007).
- Trivedi N.P., Rawal U.M.: *Indian J. Exp. Biol.* 39, 41 (2001).
- Reyes B.A., Bautista N.D., Tanquilut N.C., Anunciado R.V., Leung A.B., Sanchez G.C. et al.: *J. Ethnopharmacol.* 105, 196 (2006).
- N., Thisoda P., Rangkadilok N., Sahasitawat S., Pholphana N., Ruchirawat S. et al.: *Planta Med.* 73, 503 (2007).
- Moron M.S., Depierre J.W., Mannervik B.: *Biochim. Biophys. Acta* 582, 67 (1979).
- Ohkawa H., Ohishi N., Yagi N.: *Anal. Biochem.* 95, 351 (1979).
- Misra H.P., Fridovich I.: *Biochemistry* 15, 681 (1976).

21. Aebi H.: UV-assay of catalase. in Methods of Enzymatic Analysis, Bergmeyer H.U. Ed., vol. 2, p. 673, Verlag Chemie, Weinheim 1974.
22. Paglia D.E., Valentine W.N.: J. Lab. Clin. Med. 2, 158 (1967).
23. Cabaud P.G., Wroblewski F.: Am. J. Clin. Pathol. 30, 234 (1958).
24. Lowry O.H., Rosebrough N.J., Farr A.L., Randall R.J.: J. Biol. Chem. 193, 265 (1951).
25. Dhalla N.S., Elmoselhi A.B., Hata T., Makino N.: Cardiovas. Res. 47, 446 (2000).
26. Rajadurai M., Prince P.S.: Toxicology 232, 216 (2007).
27. Sevenian A., Hochstein P.: Ann. Rev. Nutr. 5, 365 (1985).
28. Tonomura Y., Mori Y., Torii M., Uehara T.: Toxicology 266, 48 (2009).
29. Guo Z.L., Zhao H.Y., Zheng X.H.: J. Tongji Med. Univ. 15, 205 (1995).
30. Zhang C., Kuroyangi M., Tan B.K.: Pharmacol. Res. 38, 413 (1998).
31. Woo A.Y., Waye M.M., Tsui S.K., Yeung S.T., Cheng C.H.: J. Pharmacol. Exp. Ther. 325, 226 (2008).
32. Shen Y.C., Chen C.F., Chiou W.F.: Br. J. Pharmacol. 135, 399 (2006).
33. Thisoda P., Rangkadilok N., Pholphana N., Worasuttayangkurn L., Ruchirawat S., Satayavivad J.: Eur. J. Pharmacol. 553, 39 (2006).
34. Tripathi R., Kamat J.P.: Indian J. Exp. Biol. 45, 959 (2007).
35. Wu T.S., Chern H.J., Damu A.G., Kuo P.C., Su C.R., Lee E.J. et al.: J. Asian Nat. Prod. Res. 10, 17 (2008).
36. Kamdem R.E., Sang S., Ho C.T.: J. Agric. Food Chem. 50, 4662 (2002).

Received: 04. 02. 2011